

All-ceramic crowns on deciduous canines: multidisciplinary approach

Pedro Ferrás FERNANDES^a, Tiago Coutinho ALMEIDA^b, João SAMPAIO-FERNANDES^c,
Miguel Gonçalves PINTO^d, Paulo Antunes GUIMARÃES^e

^aMaster in Implantology, Assistant of Fixed Prosthodontics, Faculty of Dentistry of Porto, Portugal

^bAssistant of Fixed Prosthodontics, Faculty of Dentistry of Porto, Portugal

^cProfessor of Fixed Prosthodontics, Faculty of Dentistry of Porto, Portugal

^dProfessor of Periodontics, Faculty of Dentistry of Porto, Portugal

^ePhD Student, Faculty of Dentistry of Porto, Portugal

Fernandes PF, Almeida TC, Sampaio-Fernandes J, Pinto MG, Guimarães PA. Coroas totalmente cerâmicas em caninos decíduos: abordagem multidisciplinar. Rev Odontol UNESP. 2010; 39(6): 373-378.

Resumo

Introdução: Qualquer dente pode se tornar permanentemente impactado. Nos casos de dentes anteriores impactados, a harmonia e a estética de um sorriso pode ser diminuída. Existem três opções principais: a observação (sem tratamento), o deslocamento (tratamento ortodôntico ou cirúrgico) e a extração. **Objetivo:** O objetivo deste trabalho é discutir as várias possibilidades de tratamento para os casos de caninos maxilares impactados bilateral, bem como para explicar os aspectos clínicos que devem ser levados em consideração. **Descrição do caso:** Este trabalho descreve uma situação clínica de impactação dos dois caninos maxilares, resolvida através da extração de ambos os caninos permanentes, seguida da colocação de coroas cerâmicas nos caninos decíduos, após gengivectomia. **Conclusão:** Apesar de terem surgido algumas dificuldades durante o tratamento, tais como a baixa posição da margem gengival, a abordagem multidisciplinar do tratamento descrito foi adequada para alcançar um sorriso agradável e uma oclusão funcional.

Palavras-chave: Coroa dentária; dente decíduo; estética.

Abstract

Introduction: Any permanent tooth may become impacted. In cases of anterior teeth impaction, the harmony and aesthetics of a smile are sometimes diminished. There are three main treatment options: observation (no treatment), relocation (orthodontic therapy or surgical) and extraction. **Objective:** The objective of this case report is to discuss the various treatment possibilities towards bilateral maxillary canine impaction as well as to explain the clinical considerations that must be taken into account. **Case description:** This paper presents a clinical situation of bilateral maxillary canine impaction solved by the extraction of both teeth and followed by the placement of ceramic crowns on the deciduous canines, as well as a corrective gingivectomy. **Conclusion:** Despite some difficulties emerged during the treatment such as the low position of the gingival margin, the authors believe that the multidisciplinary approach of the treatment described is one good option to achieve a pleasant smile and functional occlusion.

Keywords: Tooth crown; tooth deciduous; esthetics.

INTRODUCTION

Impacted teeth are those with a delayed eruption time or that are not expected to erupt completely based on clinical and radiographic assessment¹. Any permanent tooth may become impacted, and the incidence of tooth impaction varies from 5.6 to 18.8% of the population². After the third molars, maxillary canines are the most frequently impacted teeth. Their incidence

ranges between 1 and 3% in the general population¹⁻⁴ and is twice more common in females (1.17%) than in males (0.51%)⁵. Among impacted canines, 8% seem to be bilateral^{3,5}. The maxillary canine not only has the longest period of development, but also has the longest and most tortuous path of eruption from its point of formation to its final destination in the dental arch^{1,5-7}.

The etiology of canine impaction may include tooth size-arch length discrepancies, prolonged retention or early loss of deciduous canines, abnormal position of the tooth bud, ankylosis, cystic or neoplastic formation, root dilacerations, the presence of an alveolar cleft and other iatrogenic or traumatic factors^{1,3,5}.

The permanent canines are the basis of an aesthetic smile and functional occlusion¹, and any factors that interfere with their development and eruption can have serious consequences. Although extraction of primary canines can be beneficial in specific cases, inappropriate extraction of primary maxillary canines must be avoided, due to the increased potential for arch collapse and arch crowding, which could lead to a buccal impaction.

Unerupted permanent canines may cause several problems for patients, compromising the esthetics. Nevertheless, some of these teeth remain unerupted and asymptomatic for many years^{4,8}.

There are three main treatment options for impacted teeth: observation (no treatment), relocation (orthodontic therapy or surgical) and extraction^{2,9}.

1. Observation

Some authors^{4,8} recommend the early detection of impacted maxillary canines because of the unpredictable and rapid resorption of the maxillary incisor roots. The eruption path of the maxillary canine is not radiographically predictable before 10 years of age.

2. Postimpaction Observation

Attempting to reposition an impacted tooth into the alveolar process is not always warranted. Complications associated with treatment must be weighed against possible pathological concerns associated with observation.

Difficulties resulting from treatment include osseous defects, root fracture, root resorption, short root development, the need for endodontic therapy and periodontitis².

If a decision not to treat is made, periodic observation is recommended. If a decision to treat is made, treatment should be as minimal as needed to ease natural eruption, allowing normal septal development and helping in the establishment of adequate bands of keratinized gingivae.

3. Surgical Relocation (Autotransplantation)

Is also a plausible solution for treating impacted permanent teeth. Indications for surgical repositioning include the patient's age, the need to minimize or eliminate orthodontic treatment and patient compliance.

The adult patient may not wish or be able to follow the strict protocol of extended orthodontic care. Complications associated with autotransplanted teeth are devitalization, pulpal obliteration, periodontal compromises, root resorption and tooth loss².

4. Orthodontic Relocation

The prognosis depends on the position and angulation of the impacted tooth, the duration of the treatment, the patient's age, the degree of patient cooperation, the available space and the presence of keratinized gingival tissue⁹.

Clinicians must bear in mind the possibility of creating periodontal problems involving an impacted tooth and/or adjacent teeth as a result of extensive osseous reduction. Moreover, possible pulpal problems and mechanical challenges may arise while attempting to erupt an impacted tooth with osseous reduction.

5. Extraction

Because it is not possible to relocate all impacted teeth within the alveolus, their removal may be indicated. Complications that are associated with the surgical removal of impacted teeth include periodontally compromising adjacent teeth, damage to adjacent teeth, root fracture, neuropathy, sinus involvement and osseous defect².

After the extraction of the permanent canine, there are several prosthetic treatment possibilities such as the removal of the deciduous canine followed by a dental implant or a removable partial denture. In addition, the deciduous canine can be preserved and restored with a ceramic crown or resin restorations.

This paper presents a case of bilateral maxillary canines impaction solved with extraction, gengivectomy and all-ceramic crowns on the deciduous canines.

CASE DESCRIPTION

This is a case of bilateral maxillary canine impaction in a 19 year-old female. Clinical and radiographic observation showed persistent deciduous canines with minimal root resorption (Figures 1 and 2). Both permanent maxillary canines were impacted horizontally with mesially positioned crowns towards the root of the central incisors. Further detailed radiographic analysis by means of apical radiographs and computer tomography showed no significant resorption of the roots of both central and lateral maxillary incisors.

The treatment chosen involved the extraction of the impacted canines, followed by a mucogingival surgery to correct the zenith point of the anterior teeth and to allow a better emergence profile. The procedure continued with the preparation for full coverage crowns with rounded shoulder termination line on both deciduous canines (Figure 3), using a rounded cylinder diamond bur (ISO 806 314 158 524 014).

The final impression was made using a double viscosity technique with Affinis® Precious polyvinylsiloxane (Coltène Whalendent, Langenau, Germany), in order to later manufacture two all-ceramic crowns (Figure 4).

After the surgical removal of the impacted canines, this prosthetic option allowed bone formation in the extraction sites (Figure 5).

DISCUSSION

1. Preventive Considerations

The impacted canine has always represented a difficult therapeutical management for the clinician. Most clinicians agree

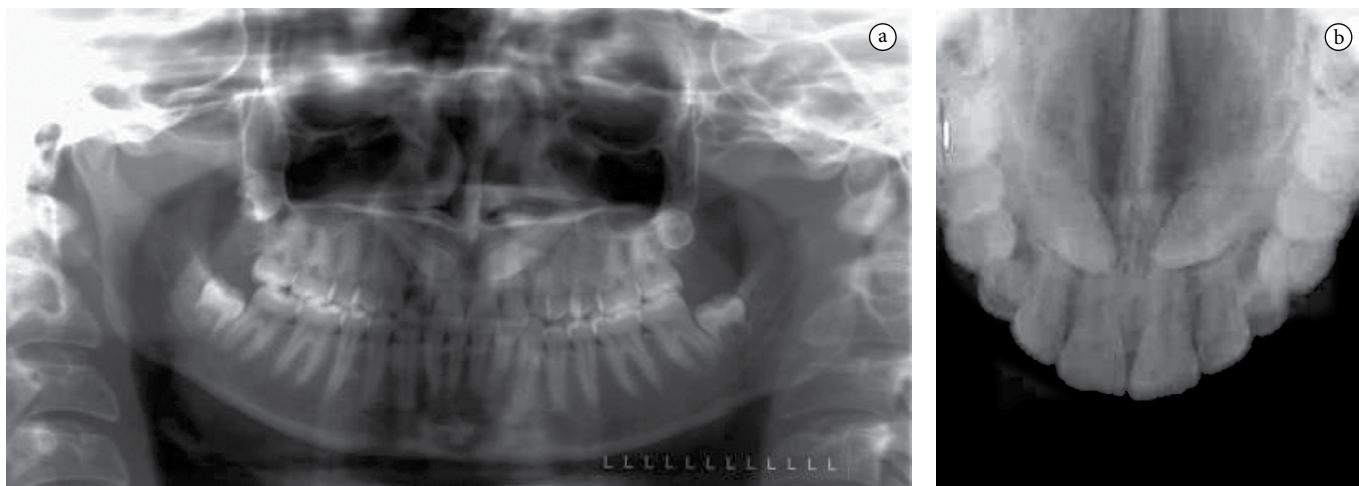


Figure 1. a-b) Initial panoramic and occlusal radiographs.

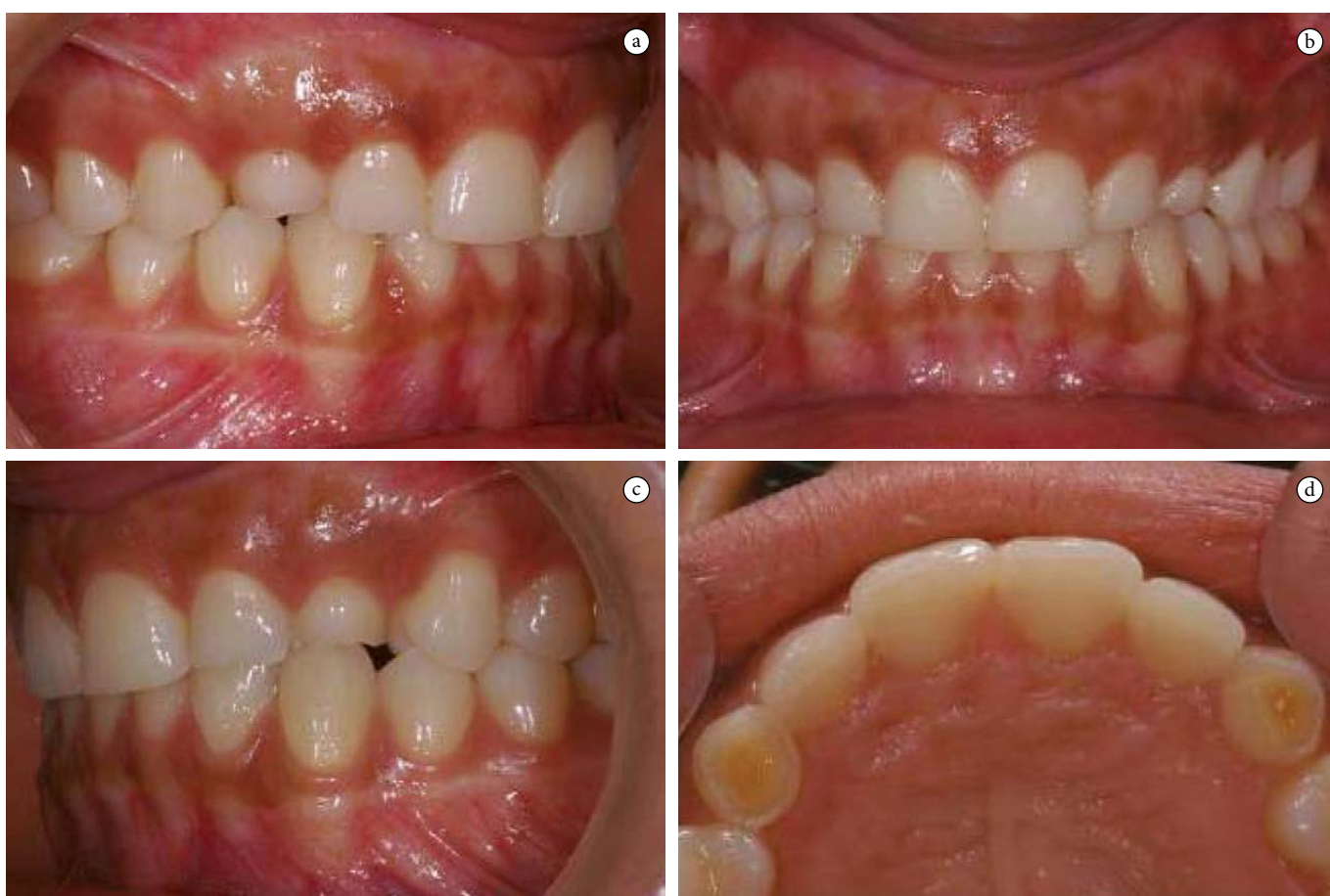

Figure 2. a-d) Initial intra-oral photographs.

that permanent canines are almost indispensable for an attractive smile and for functional occlusion⁵.

An alternative to the elected treatment could have been the extraction of the impaired deciduous canines, the surgical removal of the impacted permanent canines and their replacement by dental implants. However, the extraction of both permanent and deciduous canines followed by the immediate placement of two dental implants in the deciduous canines site could be problematic in terms of primary stability. The delayed of implant placement would imply other problems as far as the provisional

prosthesis retention is concerned (adhesive partial dentures held by teeth with short clinical crowns or removable partial denture eventually traumatic and uncomfortable).

Another option was the removal of the maxillary deciduous canines, surgical exposure of both upper maxillary canines and orthodontic extrusion using a standard fixed appliance. However, the positioning of the two impacted canines into proper alignment with the remaining permanent teeth may be difficult or not possible due to the teeth angulation and the degree of impaction¹.

For example, when a canine is labially impacted it may erupt without surgical intervention; however, palatally impacted canines rarely do so¹⁰. In addition, moving the canine to the dental arch is more time consuming in an adult than in a child. Therefore, patient must be a part of the decision-making process and be fully informed of the potential problems related to treatment¹¹.

It must be pointed out that an early detection of impacted maxillary canines may reduce treatment time, complexity, complications and cost. The ideal preventive treatment is the extraction of the primary canines when the patient is 10-13 years old¹. Moreover, an early extraction of the maxillary deciduous

canines may allow the impacted canines to correct their paths of eruption and erupt in relatively good alignment. This interceptive treatment may reduce further complications associated with palatally impacted canines, including root resorption of the lateral incisors and the need for more complex surgical and orthodontic intervention¹.

If possible, patients should be examined by the age of 8 or 9 years to determine whether the canine is displaced from a normal position in the alveolus and assess the potential for impaction³.

The patient, in this case, did not look for earlier treatment because of the aesthetically acceptable primary upper canines and asymptomatic impacted permanent canines. The patient chose to delay treatment until an aesthetic or functional need arise or the impacted teeth become symptomatic.

2. *Clinical Considerations*

2.1. *Emergence profile considerations*

The major problem in converting a deciduous canine into a permanent one by the manufacturing of all-ceramic crowns is the crown length.

Analyzing Table 1, it can be seen that the deciduous tooth has only 72% of the size of the permanent canine. In terms of mesio-distal dimensions, the values are very similar, ranging between 97% (crown) and 95% (cervix), which does not constitute a

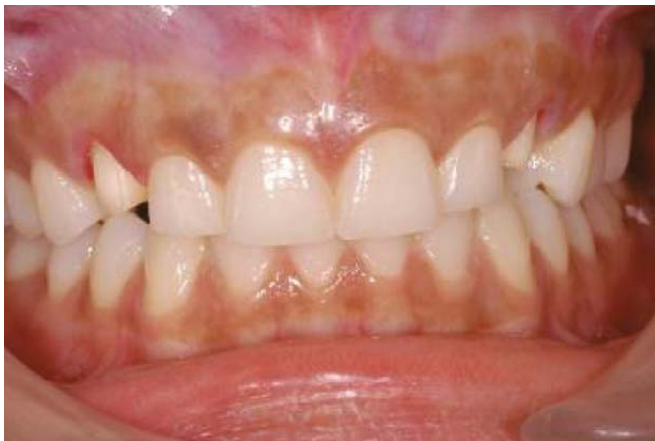

Figure 3. Teeth preparations.

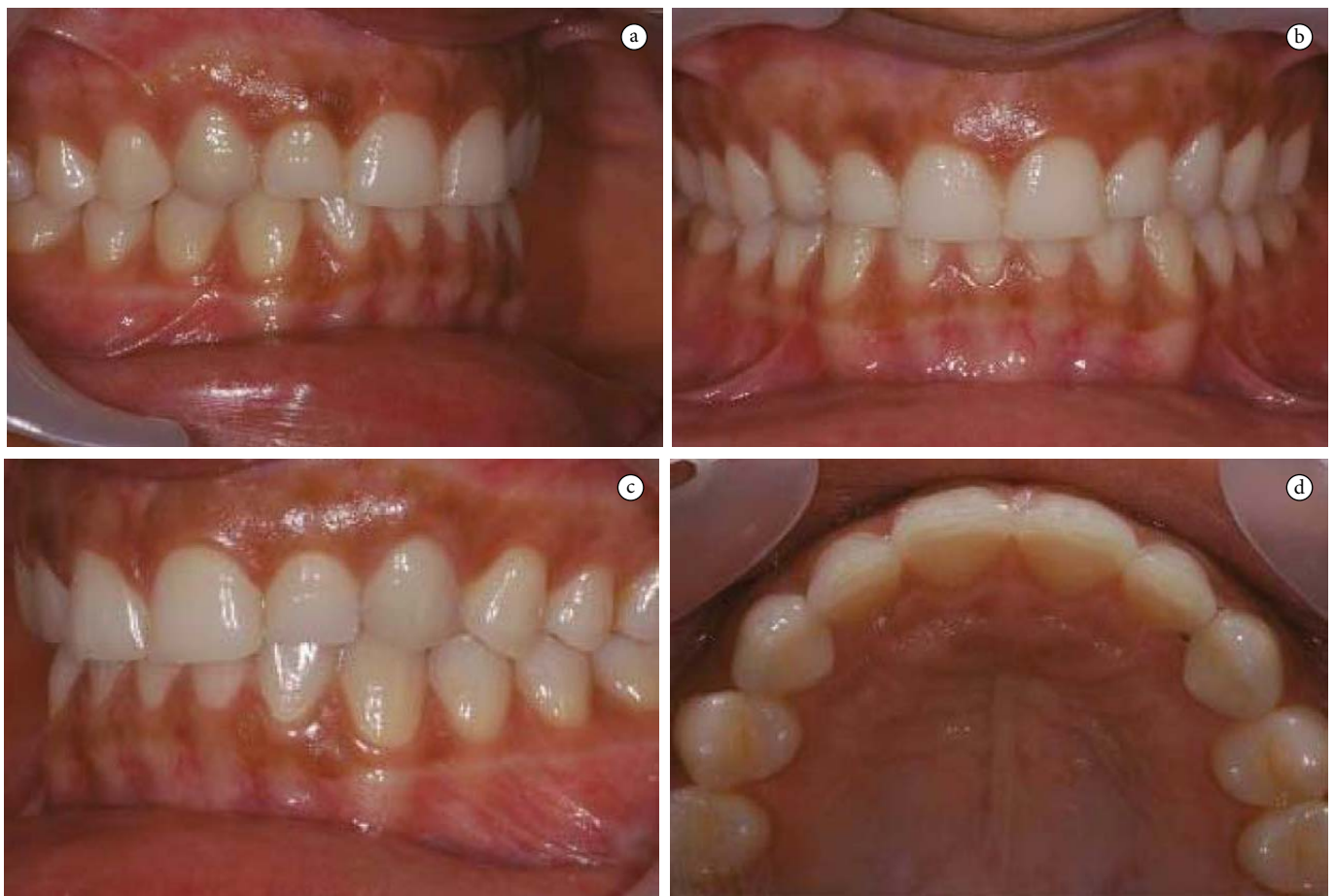
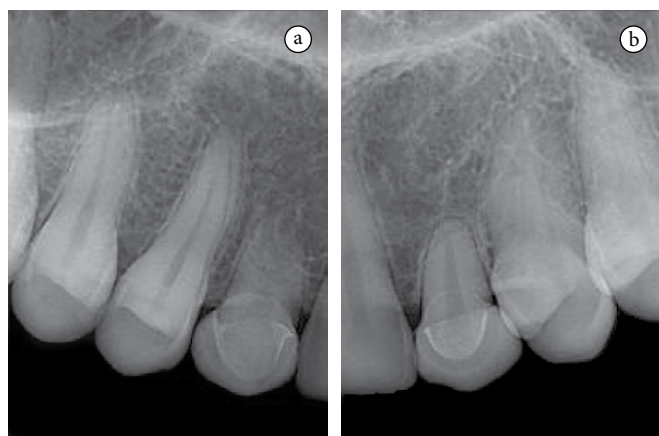
Figure 4. a-d) Clinical figures after treatment.

Table 1. Comparison between deciduous and permanent maxillary canines

Dimension measured	Permanent teeth		Deciduous teeth	
	Average (mm)	Range (mm)	Average (mm)	Percentage (%)
Crown length	10.6	8.2-13.6	7.6	72
Root length	16.5	10.8-28.5	13.5	78
Overall length	26.4	20.0-38.4	20.2	80
Crown width M-D	7.6	6.3-9.5	7.4	97
Buco-lingual crown size	8.1	6.7-10.7	5.4	67
Buco-lingual root (cervix)	7.6	6.1-10.4	5.0	66

Percentage is based on the average size for the permanent canine as equalling 100%. (Table adapted from Woelfel, Scheid¹¹ - "Dental Anatomy").

**Figure 5.** a-b) Final periapical radiographs.

problem. Regarding the bucco-lingual dimensions, and despite the values being very different, it is not aesthetically relevant.

The average root width in the cervix of the maxillary permanent canine is 7.6 mm, and in the deciduous canine is 7.4 mm. These values are very similar (95%). So, it can be concluded that, regarding the emergence profile (taking into consideration only the mesio-distal width and not the length of the tooth), there is no significant difference in making all-ceramic crowns in permanent or deciduous teeth.

2.2. Labial characteristics in the deciduous and permanent maxillary canine

Primary maxillary canine crowns may be as wide as long and constricted at the cervix. They have convex mesial and distal outlines, with distal contours more broadly rounded than mesial contours¹¹. The cervical lines of the maxillary canines are nearly flat on the labial surface. Primary maxillary canine cusps are often very sharp with two cusp ridges meeting at an acute angle. The mesial cusp slopes of these maxillary canines are longer than the distal cusp slopes (which is the exception to the rule for permanent teeth). The mesial contact area is more cervically located than the distal contact point. In the permanent maxillary canine the crown is longer in relation to its width. The outline of

the mesial side of the crown is broadly convex in the middle third becoming nearly flat in the cervical third. The distal side of the crown outline makes a swallow "s", being convex on the middle third and slightly concave in the cervical third. The mesial cusp slope of the permanent maxillary canine is shorter than the distal slope¹¹. The distal contact area is more cervically located than the mesial contact point.

2.3. Emergence profile height

One of the several difficulties that arose during the treatment was the emergence profile low position. According to Magne, Belser¹², both dental and gingival aesthetics are of major importance when looking for a harmonious smile. Even though the gingival symmetry between the canines is not primordial to achieve a good anterior aesthetics¹³ (opposite to the symmetry of the central incisors) we performed a gingivectomy on the deciduous canines to enlarge the dimension of the clinical crown and restore the balance of the gingival triangle.

With the surgery, we tried to gain a Class I gingival height^{12,14}, so that the gingival contour of the canines would be at the same level of the central incisors, leaving the contour of the lateral incisors located more coronally than the other anterior teeth.

The impaction or absence of permanent teeth may impair, in many cases, the harmony and aesthetics of a smile. In a case of impacted bilateral maxillary canines, the use of all-ceramic crowns on deciduous canines as well as a corrective gingivectomy seems to be a good option to achieve a pleasant smile and functional occlusion. This case report reveals a good aesthetic outcome and the two year follow-up appointment allowed to verify the stability of the treatment.

However, it must be pointed out that this is always a provisional treatment because, in time, the root resorption may occur leading to the tooth loss. After the surgical removal of the impacted canines, this prosthetic option also allows bone formation in the extraction sites. Therefore, if the deciduous teeth need to be extracted in the future, the placement of implants is easier and the aesthetic problem can be minimized.

REFERENCES

1. Richardson G, Russel KA. A review of impacted permanent maxillary cuspids – diagnosis and prevention. *J Can Dent Assoc.* 2000; 66: 497-501.
2. Frank CA. Treatment options for impacted teeth. *J Am Dent Assoc.* 2000; 13: 623-32.
3. Jarjoura K, Crespo P, Fines BJ. Maxillary canines impactions: orthodontic and surgical management. *Compendium Contin Educ Dent.* 2002; 23: 23-38.
4. Mazor Z, Peleg M, Redlich M. An immediate implantation into extraction sites of impacted canines combined with bone augmentation. *J Am Dent Assoc.* 1999; 130: 1767-70.
5. Bishara SE. Clinical management of impacted canines. *Semin Orthod.* 1998; 4: 87-98.
6. Mesotten K, Naert I, van Steenberghe D, Willems G. Bilaterally impacted maxillary canines and multiple missing teeth: a challenging adult case. *Orthod Craniofac Res.* 2005; 8: 29-40.
7. Olive RJ. Orthodontic treatment of palatally impacted maxillary canines. *Aust Orthod J.* 2002; 18: 64-70.
8. Crescini A, Nieri M, Buti J, Baccetti T, Mauro S, Pini Prato GP. Short- and long-term periodontal evaluation of impacted canines treated with a closed surgical-orthodontic approach. *J Clin Periodontol.* 2007; 34: 232-42.
9. Proffit WR. *Contemporary orthodontics.* St. Louis: Mosby; 1994.
10. Pearson MH, Robinson SN, Reed R, Birnie DJ, Zaki GA. Management of palatally impacted canines: the findings of a collaborative study. *Eur J Orthod.* 1998; 19: 511-5.
11. Woelfel JB, Scheid RC. *Dental anatomy: its relevance to dentistry.* 5th ed. Baltimore: Williams & Wilkins; 1997.
12. Magne P, Belser U. *Bonded porcelain restorations in the anterior dentition: a biomimetic approach.* Berlin: Quintessence; 2003.
13. Chiche GJ, Pinault A. *Esthetics of anterior fixed prosthodontics.* Berlin: Quintessence; 1994.
14. Rufenacht CR. *Fundamentals of esthetics.* Berlin: Quintessence; 1990.

AUTHOR FOR CORRESPONDENCE

Pedro Ferrás da Silva Fernandes

Master in Implantology, Assistant of Fixed Prosthodontics, Faculty of Dentistry of Porto, Portugal

e-mail: pedroferras@gmail.com

Recebido: 19/09/2010

Aceito: 31/12/2010