

Effect of laser therapy on the inflammatory response induced by endodontic medications implanted into the subcutaneous tissue of rats

Efeito da laserterapia na resposta inflamatória induzida por medicamentos endodônticos implantados em tecido subcutâneo de ratos

Felipe de Souza MATOS^{ax}, Andréa Ferreira SOARES^a, Ricardo Luiz Cavalcanti de ALBUQUERQUE JÚNIOR^b, Samuel de Oliveira RIBEIRO^a, Gustavo Danilo Nascimento LIMA^a, Sônia Maria Alves NOVAIS^a, Maria Amália Gonzaga RIBEIRO^a

^aUFS – Universidade Federal de Sergipe, Aracaju, SE, Brasil

^bUNIT – Universidade Tiradentes, Aracaju, SE, Brasil

Resumo

Introdução: Medicamentos endodônticos apresentam componentes tóxicos que provocam algum grau de reação inflamatória. **Objetivo:** Este estudo avaliou o efeito da laserterapia na resposta inflamatória causada por medicações intracanaís, em tecido subcutâneo de ratos, por meio da análise quantitativa de mastócitos. **Material e método:** Tubos de polietileno contendo as medicações foram implantados no dorso de 60 ratos, distribuídos em seis grupos: HS (pasta de hidróxido de cálcio P.A.); HL (pasta de hidróxido de cálcio P.A. e laserterapia); HPS (pasta de hidróxido de cálcio P.A. com paramonoclorofenol canforado); HPL (pasta de hidróxido de cálcio P.A. com paramonoclorofenol canforado e laserterapia); IS (iodofórmio e soro fisiológico) e IL (iodofórmio, soro fisiológico e laserterapia). Os animais foram eutanasiados oito e quinze dias após a cirurgia, as peças cirúrgicas foram removidas, processadas para inclusão em parafina e os cortes histológicos corados em Azul de Toluidina 0.2%, para quantificação dos mastócitos. A análise de variância (ANOVA) e o teste de Tukey post hoc foram aplicados para determinar diferenças significativas entre os grupos quanto ao número de mastócitos ($p < 0.05$). **Resultado:** Nos grupos HL, HPL e IL houve uma diminuição de mastócitos em ambos os períodos experimentais em relação aos grupos HS, HPS e IS, porém não se observou diferença estatística significativa entre o grupo HPS e o HPL aos oito dias. **Conclusão:** A laserterapia foi eficaz em modular a intensidade da resposta inflamatória induzida pelos medicamentos endodônticos a partir da redução significativa na quantidade de mastócitos.

Descritores: Endodontia; laserterapia; mastócitos; inflamação; subcutâneo.

Abstract

Introduction: Endodontic medications contain toxic components that cause varying degrees of inflammation. **Objective:** This study evaluated the effect of laser therapy on the inflammatory response induced by intracanal medications implanted into the subcutaneous tissue of rats using a quantitative analysis of mast cells. **Material and method:** Polyethylene tubes containing the medications were implanted in the dorsum of 60 rats divided into six groups, including HS (P.A. calcium hydroxide paste), HL (P.A. calcium hydroxide paste and laser therapy), HPS (P.A. calcium hydroxide paste with camphorated paramonochlorophenol), HPL (P.A. calcium hydroxide paste with camphorated paramonochlorophenol and laser therapy), IS (iodoform with saline) and IL (iodoform with saline and laser therapy). The animals were euthanized eight or fifteen days after surgery, and samples were removed and embedded in paraffin. Histological sections were stained with 0.2% toluidine blue for the quantification of mast cells. Analysis of variance (ANOVA) and Tukey's post-hoc test were applied to determine significant differences in the number of mast cells between groups ($p < 0.05$). **Result:** There was a decrease in mast cells for the HL, HPL and IL groups when compared with the HS, HPS and IS groups at both time points. There was no statistically significant difference between the HPS and HPL groups at the eight-day time point. **Conclusion:** Laser therapy was effective at modulating the inflammatory response induced by endodontic medications by significantly reducing the number of mast cells.

Descriptors: Endodontics; laser therapy; mast cells; inflammation; subcutaneous.

INTRODUCTION

The presence of microorganisms is considered the principal factor in the development and progression of pulp and periapical pathologies. Thus, the success of endodontic therapy depends on the complete elimination of these pathogens from the interior root canal system¹.

Biomechanical preparation combined with the action of auxiliary chemical substances with antimicrobial properties has been effective in reducing bacterial levels by providing a deep cleaning of the root canals. However, due to the presence of numerous dentinal tubules that are inaccessible to chemical-mechanical preparations, it is often necessary to use endodontic medications between sessions to eliminate or reduce the number of persistent microorganisms in the root dentin².

Among the endodontic medications commercially available, calcium hydroxide (Ca(OH)₂) is considered the intracanal medication of choice because it has multiple beneficial properties, such as satisfactory bactericidal and bacteriostatic actions, antiexudative actions and induction of mineralization³. To improve these bactericidal properties, calcium hydroxide has also been used in combination with camphorated paramonochlorophenol (PMCC) to form a paste with a greater spectrum of antimicrobial action⁴.

Another medication often used as an intracanal dressing for endodontic treatment is iodoform, a chemical with a variety of advantageous properties for bone repair, such as antimicrobial, anti-inflammatory, analgesic, deodorant and detergent activities⁵.

Despite their beneficial properties and biocompatibility with periradicular tissues, most medications used in endodontic treatments may present potentially toxic or irritating components that cause inflammation, particularly when extravasated to the periapical space⁶.

The inflammatory process that occurs in the presence of toxic components is a biological response of the organism that is characterized by the movement of specialized cells to the injury site, triggering a series of events in an attempt to restore the integrity and function of damaged tissues⁷. Among these cells, mast cells play a fundamental role in the immune response and tissue repair. The cytoplasm of mast cells contains a broad spectrum of pro-inflammatory mediators, and immunoregulatory and angiogenic molecules that participate in inflammatory reactions as well as tissue protection and repair^{8,9}.

Low-level laser therapy has been shown to be an important therapeutic tool because it can modulate the inflammation response through edema reduction, minimization of painful symptoms and cellular biostimulation to ensure rapid and efficient tissue regeneration^{10,11}. Therefore, the aim of this study was to evaluate the effect of laser therapy on the inflammatory response caused by the subcutaneous administration of intracanal medications in rats using a quantitative analysis of mast cells.

MATERIAL AND METHOD

1. Ethical Aspects and Experimental Design

Based on the ethical principles of animal experimentation established by the Brazilian College of Animal Experimentation (COBEA) and the standards of the Brazilian Society of Laboratory Animal Science (SBCAL), this study was completed after approval from the University Research Ethics Committee (protocol 180211 - CEP).

In this study, sixty male rats (*Rattus norvegicus*, Wistar strain) with an average weight between 250 and 300 g were used. The animals were randomly divided into six groups (n = 10) according to the medication used and the application of laser therapy (Table 1). The animals were euthanized eight or fifteen days after the surgical procedure.

2. Preparation of Medications and Tubes

The endodontic medications were handled in sterile glass plates following the manufacturer's recommendations. With the aid of a sterile lentulo (#25 Dentsply-Maillefer, RJ, Brazil) they were inserted in polyethylene tubes with a 4.0 mm internal diameter and 8.0 mm length. Prior to this procedure, each tube was sealed at one end with Cyanoacrylate Ester gel (Super Bonder, Aachen, Germany)^{12,13} to avoid overflow of the materials to be tested and then autoclaved in metal boxes at a temperature of 120°C for 20 minutes¹⁴.

3. Surgical Procedure

The animals were anesthetized with an intraperitoneal injection of ketamine hydrochloride (Ketamine 10%; Agener National Pharmaceutical Chemical Union, Embu, SP, Brazil) at

Table 1. The distribution of groups based on the materials tested, experimental periods and number of animals

GROUP	TESTED MATERIAL	8 DAYS	15 DAYS
HS	P.A. calcium hydroxide (3.0 g) + Saline (1.75 mL)	05	05
HL	P.A. calcium hydroxide (3.0 g) + Saline (1.75 mL) + LTR*	05	05
HPS	P.A. calcium hydroxide (3.0 g) + PMCC** + Saline (1.75 mL)	05	05
HPL	P.A. calcium hydroxide (3.0 g) + PMCC** + Saline (1.75 mL) + LTR*	05	05
IS	Iodoform (3.0 g) + Saline (1.75 mL)	05	05
IL	Iodoform (3.0 g) + Saline (1.75 mL) + LTR*	05	05

* Laser therapy; ** Camphorated paramonochlorophenol.

a dose of 0.1 mL/100 g and with the muscle relaxant thiazine hydrochloride (Rompun 2%; Bayer S.A. - Animal Health, SP, Brazil) at a dose 0.01 mL/100 g that was diluted in saline at a ratio of 1:9 and administered at a dosage of 0.25 mL/100 mg. A trichotomy and antiseptics were performed in the dorsal region of the animals with a 10% povidone-iodine topical solution (LM PHARMA®).

For the insertion of polyethylene tubes containing medication, two incisions 5 mm in width were made on the back of animals, one next to the pelvic region and another next to the scapular region. The tubes were longitudinally implanted with the open end of the tube facing the head of the animal and the sealed end of the tube facing the caudal region¹⁴. The wounds were sutured with 4-0 polyamide monofilament thread, and another antiseptics was performed with iodine alcohol¹⁵.

4. Laser Therapy Protocol

The experimental groups HL, HPL and IL underwent laser therapy and received a total of four irradiations with a 48-hour interval between sessions. The first session was immediately after surgery following the protocol described by Ribeiro et al.^{16,17}. As described in Table 2, the laser device was used according to the parameters of the irradiation Laser Diode (Twin Laser-InGaAlP/MMOPTICS, São Carlos, SP, Brazil) with a wavelength in the red spectrum ($\lambda 660$ nm). The irradiation was applied by contact at two points, one caudal and the other radial, of the surgical wound perpendicular to the long axis of the back of the animal for 120 sec per point.

5. Animal Euthanasia and Sample Preparation

Eight and fifteen days after subcutaneous implantation of the polyethylene tubes, the animals were euthanized with an overdose of Thio-Pental (Barbiturate-CRYSTALIA®) at a dose of 0.43 mL/kg. The specimens were removed from each animal

via a lozenge incision around the wound with a margin of 1 cm. Then, the samples were fixed in 10% formalin for 24 hours and processed for paraffin embedding. Histological sections with a thickness of 5 μ m were cut and then stained with 0.2% toluidine blue for the quantitative analysis of mast cells¹⁸.

6. Quantitative Analysis of Mast Cells

Mast cell counts were performed using 10 histologic fields in the area adjacent to the open end of the tube at an original magnification of 400X. A total of 10 histological sections per group were counted. The sections were examined under a standard light microscope (LEICA DM500) coupled to a computer (Pentium 133 MHz) with an image capture system. LAS EZ 2.1.0 (Leica Microsystems) software was used to obtain digital images from the histological fields analyzed.

7. Statistical Analysis

To assess the normality of the data, the Kolmogorov-Smirnov test in Minitab 15.0 software was used (Minitab Inc., PA). Statistical analysis of the mean number of mast cells obtained for each group in both experimental periods was performed using analysis of variance (ANOVA) and the Tukey test ($p < 0.05$) with the SPSS program (Version 16; SPSS, Chicago, IL).

RESULT

Histology using toluidine blue revealed globular and large mast cells that were highly granulated and stained violet due to the metachromatic property of their cytoplasmic granules. There was a wide distribution of cells in the area adjacent to the open end of the tube that contained the medications (Figure 1).

The Kolmogorov-Smirnov test was used to assess the normality of the data. The results showed the data had a normal parametric distribution ($p = 0.110$). Subsequently, an analysis of

Table 2. The irradiation parameters for a low laser power intensity

PARAMETERS	HL/HPL/IL
Emission mode	Continuous
Wavelength	660 nm
Active medium	InGaAlP
Power output	40 mW
Spot size	0.04 cm ²
Power density	1 W/cm ²
Energy density	105 J/cm ²
Time per point	120 sec
Total energy	4.8 J
Beam divergence perpendicular to the junction	17°
Tip angle	50°

Source: Tomaz et al.¹³ (2013).

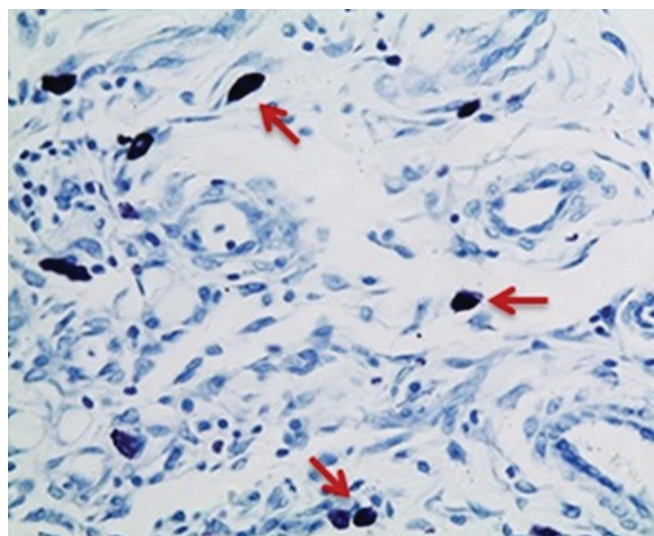


Figure 1. Photomicrograph showing the violet metachromatic staining of mast cells (arrows). Toluidine blue, 400X.

variance (ANOVA) and Tukey test with a 5% significance level was used.

Table 3 shows that analysis of variance (ANOVA) revealed a significant difference between the groups ($p < 0.001$). Thus, the Tukey's post-hoc test with a significance level of 5% was applied.

Table 4 shows the descriptive statistics, including the mean, standard deviation and standard error, for the mast cells counted in each group from both experimental periods and the results of the Tukey's post-hoc test ($p < 0.05$).

The HL and IL groups showed a significant reduction in the number of mast cells after eight days of treatment when compared with the HS and IS groups (Figure 2). Despite a decrease in the number of mast cells in the HPL group, there was no significant difference when compared with the HPS group. The laser therapy significantly reduced the number of mast cells in the HL, HPL and IL groups after 15 days of treatment when compared with their respective groups that did not receive laser therapy (HS, HPS and IS).

The HPS group showed the greatest number of mast cells after the eight-day experimental period, followed by the IS and HS groups. There were significant differences between the three groups. The HPS group maintained the highest number of mast cells after the 15-day experimental period, followed by the HS and IS groups. The significant differences between the groups remained (Figure 2).

Among the groups treated with laser therapy, the HPL group had the highest number mast cells when compared to the HL and IL groups in both experimental periods. The number of mast cells in the HL and IL groups was similar in both experimental periods.

DISCUSSION

The biological and physicochemical properties of the intracanal medications used between endodontic treatments are important for the maintenance and restoration of apical and periapical tissue integrity⁴. The presence of toxic components in the majority of intracanal medications produces a varying degree of inflammation and tissue damage in the periradicular area depending on the biocompatibility of these individual substances⁵.

In this study, laser therapy was used to minimize the irritation caused by medications that contained P.A. calcium hydroxide, P.A. calcium hydroxide with camphorated paramonochlorophenol (PMCC) or iodoform by modulating the inflammatory response. A quantitative analysis of mast cells was used to evaluate medication-induced inflammation and the efficacy of laser therapy for mitigating this response. Analysis of mast cells is a valid and simple method to determine the extent of inflammation caused by biomaterials because these cells are directly involved

Table 3. Analysis of variance (ANOVA)

	Sum of Squares	df	Mean Square	F	Sig.
Between groups	7841.613	11	712.874	102.664	.000
Within groups	333.300	48	6.944		
Total	8174.913	59			

Table 4. Descriptive statistics and Tukey test

Groups	N	Mean	Std. deviation	Std. error	Homogeneous groups*
HS 8 days	5	28.70	2.04939	.91652	c
HL 8 days	5	20.00	2.44949	1.09545	ab
HPS 8 days	5	38.70	1.98746	.88882	d
HPL 8 days	5	35.80	2.56418	1.14673	d
IS 8 days	5	34.60	3.11047	1.39104	d
IL 8 days	5	23.30	2.86356	1.28062	bc
HS 15 days	5	36.70	2.56418	1.14673	d
HL 15 days	5	17.00	2.47487	1.10680	a
HPS 15 days	5	58.00	3.04138	1.36015	e
HPL 15 days	5	23.00	3.06186	1.36931	bc
IS 15 days	5	23.30	2.51496	1.12472	bc
IL 15 days	5	15.80	2.65989	1.18954	a

*Different letters represent groups with statistically significant differences ($p < 0.05$).

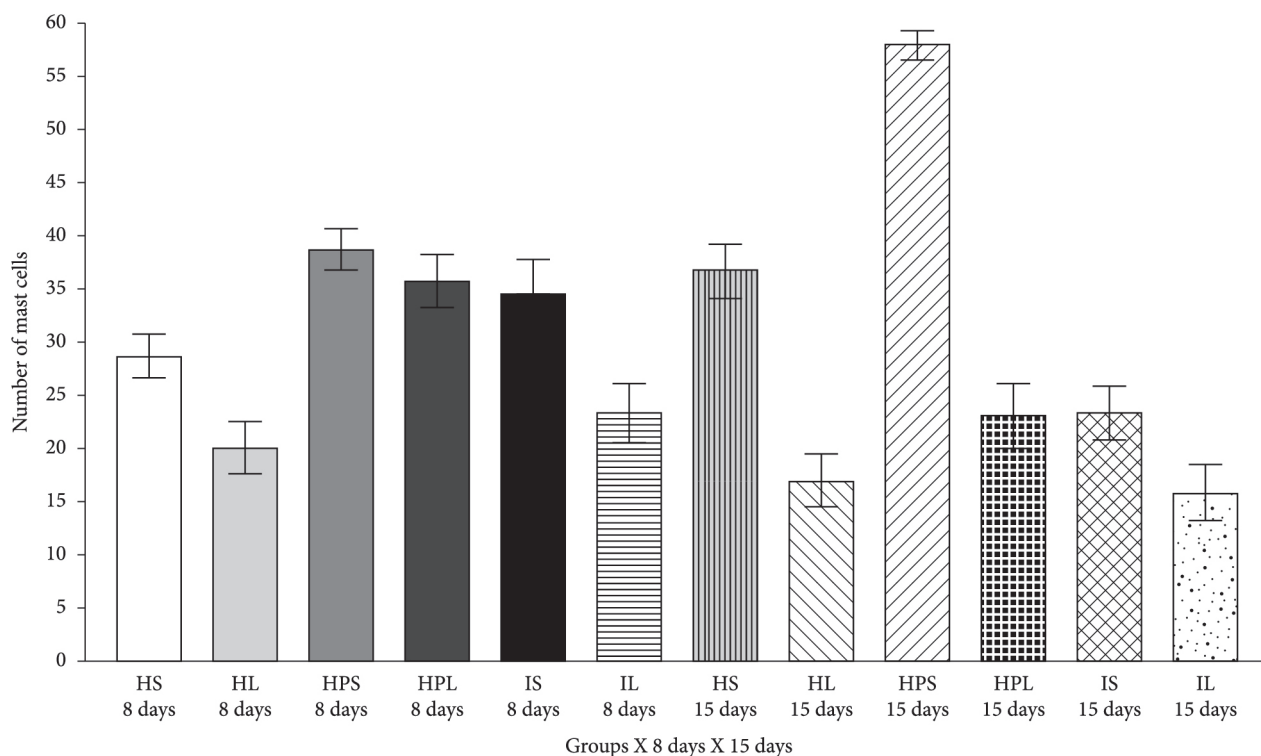


Figure 2. The average number of mast cells per group in each experimental period.

in the release of important chemical mediators that stimulate the inflammatory response¹⁹.

The tested medications were placed in polyethylene tubes to simulate a clinical condition of extravasation of endodontic material into the apical periodontium. Thus, the material comes in contact with the subcutaneous tissue only at the open end of the tube, which corresponds to the root apex^{13,20}. This methodology was introduced by Torneck²¹, who observed minimal or no tissue reaction caused by the tube, demonstrating its acceptability for the evaluation of endodontic materials.

Each tube was sealed at one end with a cyanoacrylate ester gel (Super Bonder) to avoid the extravasation of the material and establish an interface between the subcutaneous tissue and the material being investigated^{13,14}. The cyanoacrylate ester is a synthetic biological adhesive that has proven to be secure and efficacious based on its biological compatibility and high adhesion capacity in wet environments^{12,22}.

The choice of experimental periods (eight and fifteen days) was based on criteria established by the ISO 10993-6²³ and ADA^{24,25}. These criteria indicate that the initial period for histological analysis should be at least seven days post-surgery to eliminate any potential confounds from operative trauma. Based on the objectives of this study, these time periods were also chosen because they are common in the clinical use of intracanal medications, and these periods allow for observation of inflammatory and repair processes¹⁶.

A histological analysis showed that mast cells were concentrated at the material/tissue interface, suggesting that the tested materials cause tissue damage and that mast cells play a fundamental role in the organism's defense by producing a local inflammatory reaction.

This cell distribution pattern was also observed by Rezzani et al.¹⁹ and Berbert et al.²⁰. These studies showed that the frequency of mast cells was higher in areas near the implanted biomaterial, suggesting that the cells produced the inflammatory response induced by the studied materials. According to de Noronha Santos Netto et al.²⁶, a significantly greater number of mast cells was observed in lesions with inflammation based on an analysis of the frequency and distribution of mast cells in inflamed and non-inflamed cysts. These data indicate that mast cells participate in various acute and chronic inflammatory responses.

The distribution of mast cells in tissue compartments is important because they can release chemical mediators that influence the development, extension and duration of inflammatory reactions and, consequently, tissue repair²⁷. Specifically, histamine causes vasodilation, increases vascular permeability and, together with leukotrienes and prostaglandins, favors the recruitment of defense cells, such as neutrophils, eosinophils and macrophages^{28,29}.

In the present study, laser therapy effectively reduced the number of mast cells at the endodontic medication/tissue interface, thus modulating the intensity of the local inflammatory response and likely accelerating tissue repair¹⁹. The absence of a statistical significance between the HPS and HPL groups after the eight-day period may be due to a cytotoxic effect caused by the association of the medications and the low permeability of calcium hydroxide in the tissue. These effects could produce an intense inflammatory action during the first eight days that counteracts the anti-inflammatory potential of the laser. By fifteen days of treatment, a greater diffusion of these substances in

the interstitium would result in more evident effects of the laser radiation¹⁶.

Similar results were found in the work of Berbert et al.²⁰, who observed a significant decrease in the density of mast cells after treatment with a red laser ($\lambda 685$ nm) and infrared light ($\lambda 830$ nm) in rats that were subcutaneously exposed to endodontic sealer. Meireles et al.^{30,31} and Ribeiro et al.^{16,17} also evaluated the effect of a red laser ($\lambda 660$ nm) in the repair process. These authors showed that the use of the laser therapy attenuated the inflammatory reaction found in the subcutaneous tissue wounds of rats.

Ribeiro³² quantitatively evaluated mast cells during the repair process of subcutaneous wounds in the backs of rats after laser photobiomodulation at $\lambda 660$ nm and found that the overall number of mast cells decreased after laser therapy. However, no significant difference was observed in the number of mast cells among the groups at the different times analyzed.

In this study, the significant decrease in the number of mast cells in groups treated with laser therapy is likely due to the photobiomodulator properties of the laser that promotes analgesic and anti-inflammatory effects and accelerates tissue repair¹⁷. There are many different therapeutic actions of lasers on tissues, including increased local microcirculation³³, reduction of the number of inflammatory cells³⁴, inhibition of cyclooxygenase-2 (COX-2) and proinflammatory cytokine synthesis^{35,36}, increase in collagen synthesis and stimulation of the proliferation of epithelial cells and fibroblasts^{37,38}.

P.A. calcium hydroxide with camphorated paramonochlorophenol (PMCC) produced a more aggressive tissue reaction when compared with the other medications studied in both experimental periods. This result is likely due to the presence of paramonochlorophenol because it is considered a potent cytotoxic agent despite its bactericidal properties. Moreover, PMCC is a phenolic compound that releases free radicals, and the low surface tension and lipid solubility of PMCC leads to high diffusion rates in the tissue³⁹. The cytotoxic potential of calcium hydroxide is based on its alkalizing action resulting from its ionization in hydroxyl ions that cause a zone of surface protein denaturation in the surrounding tissue⁴.

The smallest number of mast cells was found in the group treated with P.A. calcium hydroxide for eight days. This effect was likely due to the excellent biological properties of P.A. calcium hydroxide, including its biocompatibility, capacity to aid in the repair of periapical lesions, antiexudative action and induction of mineralization³. Additionally, calcium hydroxide is well-tolerated by tissues because of its low solubility, which limits its cytotoxicity in the area that is in direct contact with the substance⁴. On the other hand, the lowest frequency of mast cells was found in the group treated with iodoform at 15 days. This result can be explained by the rapid elimination of iodoform by the organism, gradually minimizing any toxic effects in the adjacent tissue^{5,6}.

This work demonstrates that the endodontic medications studied present different cytotoxic potentials and that laser therapy is effective at reducing the number of mast cells at the medication/tissue interface. Thus, these data suggest that laser therapy has the capacity to modulate the intensity of the inflammatory reaction. However, new studies are needed to precisely demonstrate the relationship between the number of mast cells, the biological response to toxic components of medications and the effect of laser therapy. These future studies may provide data that can support the justification of laser therapy in clinical use.

CONCLUSION

The use of laser therapy with endodontic medications, including P.A. calcium hydroxide, P.A. calcium hydroxide with camphorated paramonochlorophenol (PMCC) and iodoform, that were implanted subcutaneously in rats significantly reduced the number of mast cells, thus modulating the local inflammatory response.

Based on the significant increase in the number of mast cells, P.A. calcium hydroxide with camphorated paramonochlorophenol (PMCC) was more irritating to the subcutaneous tissue of rats during both experimental periods when compared with the other medications. Again based on the number of mast cells, the P.A. calcium hydroxide paste and the iodoform demonstrated the highest level of biocompatibility after eight days and fifteen days of treatment, respectively.

REFERENCES

1. El Karim I, Kennedy J, Hussey D. The antimicrobial effects of root canal irrigation and medication. *Oral Surg Oral Med Oral Pathol Oral Radiol Endod.* 2007 April; 103(4): 560-9. <http://dx.doi.org/10.1016/j.tripleo.2006.10.004>. PMID:17223590.
2. Rôças IN, Siqueira JF Jr. Identification of bacteria enduring endodontic treatment procedures by a combined reverse transcriptase-polymerase chain reaction and reverse-capture checkerboard approach. *J Endod.* 2010 January; 36(1): 45-52. <http://dx.doi.org/10.1016/j.joen.2009.10.022>. PMID:20003934.
3. Ferracane JL, Cooper PR, Smith AJ. Can interaction of materials with the dentin-pulp complex contribute to dentin regeneration? *Odontology.* 2010 February; 98(1): 2-14. <http://dx.doi.org/10.1007/s10266-009-0116-5>. PMID:20155502.
4. Lopes HP, Siqueira JF Jr. *Endodontia: biologia e técnica.* Rio de Janeiro: Guanabara Koogan; 2010.
5. Fernandes KPS, Puertas KV, Bussadori SK, Pavesi VCS, Martins MD. Análise comparativa in vivo da biocompatibilidade de pastas de iodofórmio. *Rev ABO Nac.* 2008; 15(6): 342-6.
6. Cerqueira DF, Mello-Moura AC, Santos EM, Guedes-Pinto AC. Cytotoxicity, histopathological, microbiological and clinical aspects of an endodontic iodoform-based paste used in pediatric dentistry: a review. *J Clin Pediatr Dent.* 2008; 32(2): 105-10. PMID:18389674.
7. Kapoor P, Sachdeva S, Sachdeva S. Topical hyaluronic Acid in the management of oral ulcers. *Indian J Dermatol.* 2011 May; 56(3): 300-2. <http://dx.doi.org/10.4103/0019-5154.82485>. PMID:21772592.

8. Michailidou EZ, Markopoulos AK, Antoniadis DZ. Mast cells and angiogenesis in oral malignant and premalignant lesions. *Open Dent J.* 2008; 2(1): 126-32. <http://dx.doi.org/10.2174/1874210600802010126>. PMID:19444318.
9. Moon TC, St Laurent CD, Morris KE, Marcet C, Yoshimura T, Sekar Y, et al. Advances in mast cell biology: new understanding of heterogeneity and function. *Mucosal Immunol.* 2010 March; 3(2): 111-28. <http://dx.doi.org/10.1038/mi.2009.136>. PMID:20043008.
10. Marinho RR, Matos RM, Santos JS, Ribeiro MAG, Smianotto S, Barreto EO, et al. Potentiated anti-inflammatory effect of combined 780 nm and 660 nm low level laser therapy on the experimental laryngitis. *J Photochem Photobiol B.* 2013 April; 121: 86-93. <http://dx.doi.org/10.1016/j.jphotobiol.2013.02.012>. PMID:23524249.
11. Maia MLM, Bonjardim LR, Quintans JS, Ribeiro MAG, Maia LGM, Conti PCR. Effect of low-level laser therapy on pain levels in patients with temporomandibular disorders: a systematic review. *J Appl Oral Sci.* 2012 November-December; 20(6): 594-602. <http://dx.doi.org/10.1590/S1678-77572012000600002>. PMID:23329239.
12. Souza SC, Briglia C, Costa SRMR. Reparo de feridas cutâneas usando cola cirúrgica de baixo custo. *An Bras Dermatol.* 2012; 87(2): 241-9. PMID:22570028.
13. Tomaz PJS, Farias MP, Piva MR, Albuquerque Júnior RLC, Ribeiro MAG. Effect of laser therapy in inflamed tissue by medications based on iodoform laser therapy in inflamed tissue. *Am J Appl Sci.* 2013; 10(1): 81-8. <http://dx.doi.org/10.3844/ajassp.2013.81.88>.
14. Garcia LFR, Lia RCC, Lopes RA, Oliveira DA, Pires-de-Souza FCP, Santos HSL. Análise morfológica e morfométrica do tecido subcutâneo de ratos submetidos à ação de pasta de hidróxido de cálcio e óleo de *Ricinus communis*. *Ciênc Odontol Bras.* 2008; 11(3): 47-54.
15. Sassioto MCP, Inouye CM, Aydos RD, Figueiredo AS, Pontes ERJC, Takita LC. Estudo do reparo ósseo com matriz óssea bovina desvitalizada e calcitonina em ratos. *Acta Cir Bras.* 2004; 19(5): 495-503. <http://dx.doi.org/10.1590/S0102-86502004000500007>.
16. Ribeiro MAG, Albuquerque RL Jr, Ramalho LM, Pinheiro AL, Bonjardim LR, Da Cunha SS. Immunohistochemical assessment of myofibroblasts and lymphoid cells during wound healing in rats subjected to laser photobiomodulation at 660 nm. *Photomed Laser Surg.* 2009 February; 27(1): 49-55. <http://dx.doi.org/10.1089/pho.2007.2215>. PMID:19250051.
17. Ribeiro MAG, Albuquerque-Júnior RLC, Barreto ALS, Oliveira VGAM, Santos TB, Dantas CDF. Morphological analysis of second-intention wound healing in rats submitted to 16 J/cm² λ 660-nm laser irradiation. *Indian J Dent Res.* 2009; 20(3): 390. <http://dx.doi.org/10.4103/0970-9290.57360>.
18. Michalany J. Técnica histológica em anatomia patológica. São Paulo: Pedagógica e Universitária; 1980.
19. Rezzani R, Rodella L, Tartaglia GM, Paganelli C, Sapelli P, Bianchi R. Mast cells and the inflammatory response to different implanted biomaterials. *Arch Histol Cytol.* 2004 September; 67(3): 211-7. <http://dx.doi.org/10.1679/aohc.67.211>. PMID:15570886.
20. Berbert FLCV, Sivieri-Araújo G, Ramalho LTO, Pereira SAL, Rodrigues DBR, de Araújo MS. Quantification of fibrosis and mast cells in the tissue response of endodontic sealer irradiated by low-level laser therapy. *Lasers Med Sci.* 2011 November; 26(6): 741-7. <http://dx.doi.org/10.1007/s10103-010-0797-6>. PMID:20549281.
21. Torneck CD. Reaction of rat connective tissue to polyethylene tube implants. I. *Oral Surg Oral Med Oral Pathol.* 1966 March; 21(3): 379-87. [http://dx.doi.org/10.1016/0030-4220\(66\)90077-6](http://dx.doi.org/10.1016/0030-4220(66)90077-6). PMID:5216747.
22. Bozkurt MK, Saydam L. The use of cyanoacrylates for wound closure in head and neck surgery. *Eur Arch Otorhinolaryngol.* 2008 March; 265(3): 331-5. <http://dx.doi.org/10.1007/s00405-007-0454-2>. PMID:17899144.
23. ISO 10993-6. Biological evaluation of medical devices – part 6: tests for local effects after implantation. 2007. Available from: <http://www.iso.org>.
24. American Dental Association. Standardization programs for dental materials and devices: Council on Dental Materials and Devices. *J Am Dent Assoc.* 1972 February; 84(2): 375-81. PMID:4500355.
25. American National Standards. American Dental Association. Document nº 41 for recommended standard practices for biological evaluation of dental materials. New York: ANSI/ADA; 1982.
26. de Noronha Santos Netto J, Pires FR, da Fonseca EC, Silva LE, de Queiroz Chaves Lourenço S. Evaluation of mast cells in periapical cysts, dentigerous cysts, and keratocystic odontogenic tumors. *J Oral Pathol Med.* 2012 September; 41(8): 630-6. <http://dx.doi.org/10.1111/j.1600-0714.2012.01126.x>. PMID:22280463.
27. Galli SJ, Tsai M. Mast cells: versatile regulators of inflammation, tissue remodeling, host defense and homeostasis. *J Dermatol Sci.* 2008 January; 49(1): 7-19. <http://dx.doi.org/10.1016/j.jdermsci.2007.09.009>. PMID:18024086.
28. Rodewald HR, Feyerabend TB. Widespread immunological functions of mast cells: fact or fiction? *Immunity.* 2012 July; 37(1): 13-24. <http://dx.doi.org/10.1016/j.immuni.2012.07.007>. PMID:22840840.
29. Pejler G, Knight SD, Henningson F, Wernersson S. Novel insights into the biological function of mast cell carboxypeptidase A. *Trends Immunol.* 2009 August; 30(8): 401-8. <http://dx.doi.org/10.1016/j.it.2009.04.008>. PMID:19643669.
30. Meireles GC, Santos JN, Chagas PO, Moura AP, Pinheiro AL. Effectiveness of laser photobiomodulation at 660 or 780 nanometers on the repair of third-degree burns in diabetic rats. *Photomed Laser Surg.* 2008 February; 26(1): 47-54. <http://dx.doi.org/10.1089/pho.2007.2051>. PMID:18248161.
31. Meirelles GC, Santos JN, Chagas PO, Moura AP, Pinheiro AL. A comparative study of the effects of laser photobiomodulation on the healing of third-degree burns: a histological study in rats. *Photomed Laser Surg.* 2008 April; 26(2): 159-66. <http://dx.doi.org/10.1089/pho.2007.2052>. PMID:18338966.
32. Ribeiro MAG. Estudo morfológico, histoquímico e imuno-histoquímico do processo de reparo subcutâneo em ratos submetidos a fotobiomodulação à laser λ660nm [tese doutorado]. Salvador: Universidade Federal da Bahia; 2006.
33. Lins RDAU, Dantas EM, Lucena KCR, Catão MHCV, Granville-Garcia AF, Carvalho Neto LG. Efeitos bioestimulantes do laser de baixa potência no processo de reparo. *An Bras Dermatol.* 2010; 85(6): 849-55. <http://dx.doi.org/10.1590/S0365-05962010000600011>. PMID:21308309.
34. Paiva-Oliveira EL, Lima NC, Silva PH, Sousa NTA, Barbosa FS, Orsini M, et al. Low-level laser therapy (LLLT) reduces inflammatory infiltrate and enhances skeletal muscle repair: histomorphometric parameters. *Laser Phys.* 2012; 22(9): 1425-30. <http://dx.doi.org/10.1134/S1054660X12090113>.

35. Sakurai Y, Yamaguchi M, Abiko Y. Inhibitory effect of low-level laser irradiation on LPS-stimulated prostaglandin E2 production and cyclooxygenase-2 in human gingival fibroblasts. *Eur J Oral Sci.* 2000 February; 108(1): 29-34. <http://dx.doi.org/10.1034/j.1600-0722.2000.00783.x>. PMID:10706474.
36. Esteves Junior I, Masson IB, Oshima CTF, Paiotti APR, Liebano RE, Plapler H. Low-level laser irradiation, cyclooxygenase-2 (COX-2) expression and necrosis of random skin flaps in rats. *Lasers Med Sci.* 2012 May; 27(3): 655-60. <http://dx.doi.org/10.1007/s10103-011-1011-1>. PMID:22016040.
37. Dantas MDM, Cavalcante DRR, Araújo FEN, Barretto SR, Acirole GT, Pinheiro AL, et al. Improvement of dermal burn healing by combining sodium alginate/chitosan-based films and low level laser therapy. *J Photochem Photobiol B.* 2011 October; 105(1): 51-9. <http://dx.doi.org/10.1016/j.jphotobiol.2011.06.009>. PMID:21803596.
38. Rodrigues SSMRG, Maior BSS, Aquino DR, Anbinder AL. Effects of low power laser under diferente protocols, in the repair of skin wounds in rats. *Clin Pesquisa Odontol UNITAU.* 2009; 1: 31-7.
39. Leonardo MR. *Endodontia: tratamento de canais radiculares: princípios técnicos e biológicos.* São Paulo: Artes Médicas; 2008.

CONFLICTS OF INTERESTS

The authors declare no conflicts of interest.

*CORRESPONDING AUTHOR

Felipe de Souza Matos

Rua Fátima Maria Chagas, 480, Bellagio Residence, Edifício San Lourenzo, Apto. 106, Bairro Jabotiana, 49095-793 Aracaju - SE, Brasil
e-mail: felipe_smatos@hotmail.com

Received: September 7, 2013

Accepted: May 27, 2014